

Journal of Oral Medicine and Dental Research

Genesis-JOMDR-6(1)-81
Volume 6 | Issue 1
Open Access
ISSN: 2583-4061

Innovative Protocol for Early Class III Correction with Aligner and Facemask: A Case Report

Romina Vignolo Lobato^{1*}, and David Gonzalez Zamora²

¹*Professor of the Master's Degree in Advanced Orthodontics. European University of Madrid, Professor of the Master's Degree in Orthodontics and Orthopaedics. San Pablo CEU University – Madrid, Exclusive Private Practice in Madrid

²Professor of the Master's Degree in Orthodontics and Orthopaedics. San Pablo CEU University - Madrid. Exclusive Private Practice in Madrid

***Corresponding author:** Romina Vignolo Lobato, Avenida Dr. Marañón 17 1º A. Majadahonda . 28220. Madrid, Spain

Citation: Vignolo Lobato R and Gonzalez Zamora D. Innovative Protocol for Early Class III Correction with Aligner and Facemask : A Case Report . J Oral Med and Dent Res. 6(1):1-16.

Received: October 11, 2024 | **Published:** January 10, 2025

Copyright © 2025 genesis pub by Vignolo Lobato R, et al. CC BY-NC-ND 4.0 DEED. This is an open-access article distributed under the terms of the Creative Commons Attribution-Non Commercial-No Derivatives 4.0 International License. This allows others distribute, remix, tweak, and build upon the work, even commercially, as long as they credit the authors for the original creation

Abstract

The purpose of this case report is to describe the treatment of a Class III malocclusion in the primary dentition using maxillary expansion with aligners, in combination with a facemask anchored to buttons or hooks integrated into the aligners. The treatment objectives included correcting anterior and posterior crossbites, achieving maxillary protrusion through maxillary traction, improving mandibular dynamics, and balancing the facial profile. Skeletal and dental changes were evaluated, revealing a significant increase in the SNA angle and harmonization of the anteroposterior relationship according to Wits values. Vertical skeletal characteristics remained stable throughout the treatment.

Case Report: Vignolo Lobato R, et al. J Oral Med Dent Res. 2025, 6(1)-81

DOI: [https://doi.org/10.52793/JOMDR.2025.6\(1\)-81](https://doi.org/10.52793/JOMDR.2025.6(1)-81)

The success of the treatment is attributed to accurate diagnosis, appropriate planning, and strong patient and family compliance. The results underscore the importance of early intervention in Class III malocclusion, particularly when the maxilla is the primary etiological factor, highlighting the crucial role of orthopedic appliances and treatment adherence in achieving favorable craniofacial growth.

Keywords

Class III treatment; Maxillary hypoplasia; Expansion; Palatal expansion technique; Face mask therapy; Interceptive orthodontics; Orthopedics; orthodontic.

Introduction

Class III malocclusion is one of the most notorious malocclusions, and is therefore often identified early, since differences in skeletal size, already exist regarding occlusion Class I as early as 4-5 years of age [1]. It has been documented that Class III malocclusion tends to exacerbate during growth, especially from adolescence onwards. Therefore, in children, this malocclusion may not be fully defined, and unestablished facial and occlusal features may make diagnosis difficult [2]. The earlier the interceptive phase is initiated, the greater the orthopedics effects, often to the detriment of the inevitable orthodontic effects [3]. In Class III malocclusion, the mandibular arch is more advanced relative to the maxillary arch, and this condition tends to worsen with age, which has led to controversy among researchers regarding diagnosis, prognosis and treatment [4].

The etiology of this problem may be of genetic origin [5], which is associated with a poorer prognosis [6], or of environmental origin, influenced by a more anterior and inferior position of the tongue [7], as well as by habits and oral breathing [8]. According to the WHO, this type of alteration ranks third after dental caries and periodontitis [9]. Its incidence varies among different ethnic groups, ranging from 0 to 26% worldwide [10,11]. The prevalence of Class III malocclusions also varies considerably, ranging from 1 to 4 % in Caucasians, 4 to 12 % in Chinese and 9 to 19 % in Koreans [12,13].

In relation to etiology and underlying skeletal dysmorphia, several studies have indicated that both mandibular prognathism and maxillary retrognathism are equally frequent in individuals with Class III anomalies (with a range of 32 to 63 % of patients presenting with a retrusive maxilla) [14,16]. Furthermore, in the majority of patients, a combination of both skeletal aberrations is observed. With an increasing number of studies highlighting the maxillary component in Class III skeletal patterns [17, 18], and with the understanding that the therapeutic influence on the growing mandible is limited (and may involve unwanted side effects for the temporomandibular joint), the standard therapy for mild to moderate Class III discrepancies, especially in growing patients, is maxillary protraction to correct the maxillary deficiency.

Early treatment of Class III malocclusion aims to create an environment conducive to proper dentofacial development in order to prevent progressive hard and soft tissue changes, improve skeletal discrepancies and provide optimal conditions for future craniofacial growth. This early approach offers benefits in aesthetics and facial profile, prevents periodontal recession and tooth wear, improves temporomandibular joint (TMJ) function, reduces negative psychosocial effects in children and reduces the need for orthognathic surgery, thus simplifying later therapeutic phases [19. 21]. In addition, when

the face mask is combined with maxillary expansion, an increase in airway volume is achieved, resulting in improved respiratory function [22-24].

The purpose of this case report is to describe the treatment of a Class III malocclusion in the primary dentition using maxillary expansion with clear aligners in combination with a face mask with button or hook traction integrated into the aligner.

Development

Maxillary expansion and anterior traction facial mask

The treatment of the spectrum of Class III malocclusions represents one of the most complex challenges in the field of orthodontics and orthopedic orofacial therapy. Since the late 19th century, a variety of treatment strategies have been proposed, ranging from the use of functional appliances [25-27], chin rest therapy [28, 29] and face mask therapy [30-34] to surgical correction by split sagittal osteotomy and LeFort I osteotomy.

There are few systematic literature review studies, and even fewer including statistical meta-analyses on the effects and effectiveness of maxillary protraction therapy with the use of an orthopedic face mask [35-37]. The influence and possible improvement of maxillary protraction through maxillary expansion has been the subject of debate [38-42]. In a 1999 review, concluded that expansion slightly improves the effect of maxillary protraction and reduces tooth movement, although they noted that the clinical significance is low [35]. The review of face mask therapy, conducted by Cordasco et al. and published in 2014, also partially addressed the aspect of expansion, indicating that no significant improvement was observed with rapid palatal expansion [37]. In 2005, introduced a novel approach, proposing a protocol of alternating activation and deactivation of the maxillary expansion appliance (altRAMEC) prior to the application of class III mechanics, which improved the therapeutic effect in the hypoplastic maxilla [43].

The treatment of Class III malocclusion in growing patients with the use of a face mask is effective for the correction of sagittal discrepancy. The need for a single transverse expansion is mainly determined by dentoalveolar anomalies in the transverse dimension, such as edge-to-edge occlusion or crossbites. Recent findings underline that there is no significant improvement in maxillary protraction when additional expansion is performed [44].

Similarly, the literature includes studies comparing the effectiveness of clear aligners with rapid maxillary expansion (RME) in terms of maxillary expansion. Although further research is needed to confirm these findings, the available data indicate a significant increase in palatal volume, as well as in other evaluated parameters such as air volume. While cases treated with rapid palatal expanders demonstrate a slight superiority over clear aligners in all evaluated parameters, this difference has not been found to be statistically significant [45-47].

Several clinical studies, systematic reviews and meta-analyses have demonstrated the skeletal effects of face mask treatment, both in combination with and without rapid maxillary expansion (RME) as described.

Thermoplastic materials, trimline on the aligner and integrated attachments for maxillary traction

Thermoplastic materials

Transparent aligners are manufactured from various thermoplastic materials, the properties of which are altered during the thermoforming process. In addition, the intraoral environment significantly influences the performance of these aligners. According to [48], the mechanical characteristics of the polymer used, the daily frequency with which the aligner is removed and the magnitude of tooth activation are determining factors in the forces generated by the aligner [49].

Currently, thermoplastic materials used in the manufacture of aligners include polyethylene terephthalate (PET-G), polypropylene, polycarbonate (PC), thermoplastic polyurethanes (TPU) and vinyl ethyl acetate [50].

In our proposed protocol, a specific combination of aligners is used at each stage of treatment: initially, a PET-G aligner, followed by a TPU aligner. In the proposed protocol, a specific combination of aligners is used at each stage of treatment: initially, a thermoformed multilayer copolyester and polyurethane composite (TPU + PET-G) plastic, followed by a TPU aligner. Previous studies have demonstrated that the forces applied by multilayer TPU + PET-G aligners significantly decrease during the first eight hours of wear, after which they reach a point of stability [51]. This system counteracts the reduction in force by utilizing two aligners per stage; the first, a TPU + PET-G multilayer aligner, is worn during the initial days, followed by a new polyurethane (TPU) aligner, which has shown less force degradation compared to other materials [52].

The combination of these two types of materials improves the predictability of complex tooth movements, ensuring more effective control of mass shifts and torque changes.

Variable trimline

The trimline on orthodontic aligners refers to the edge that delineates how far the aligner extends over the tooth and gum. This trimline can influence several aspects of aligner treatment, including:

1. Tooth movement,
2. Patient comfort,
3. Aligner stability
4. Aesthetics [53-55].

It is critical that the trimline be straight and 2.5 mm above the gingival margin to meet specific protocol requirements and achieve the desired dentoalveolar and skeletal movement (Figure 1).

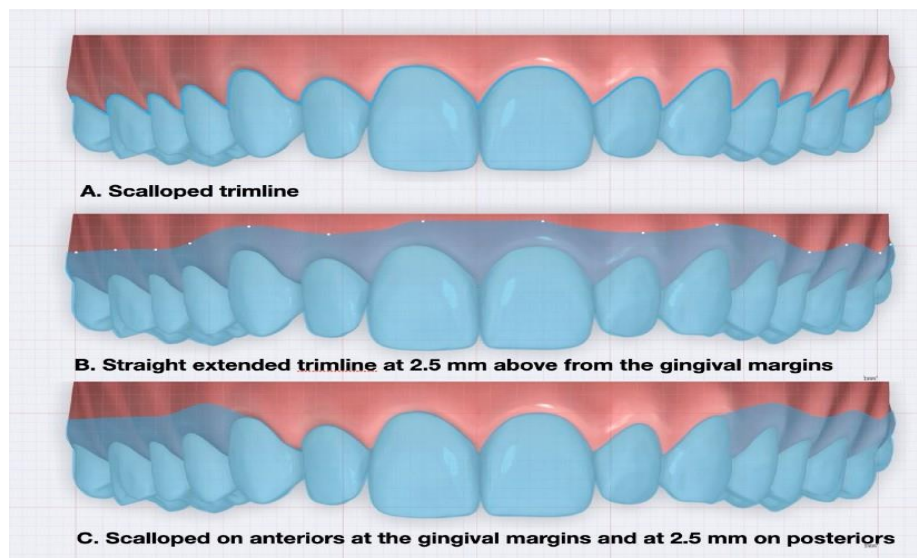


Figure 1: Variable trim line.

Buttons and Hooks Integrated into The Aligner

Buttons and hooks integrated directly into the aligners provide an additional attachment point for the use of elastics during treatment. This tool can be added to any part of the aligner allowing the elastics for traction to the face mask to engage in any direction. With a solid structure they are designed to facilitate efficient tooth movement, allowing the teeth to move without being directly affected by the forces of the elastics, withstanding a force of up to 500g (Figure 2).

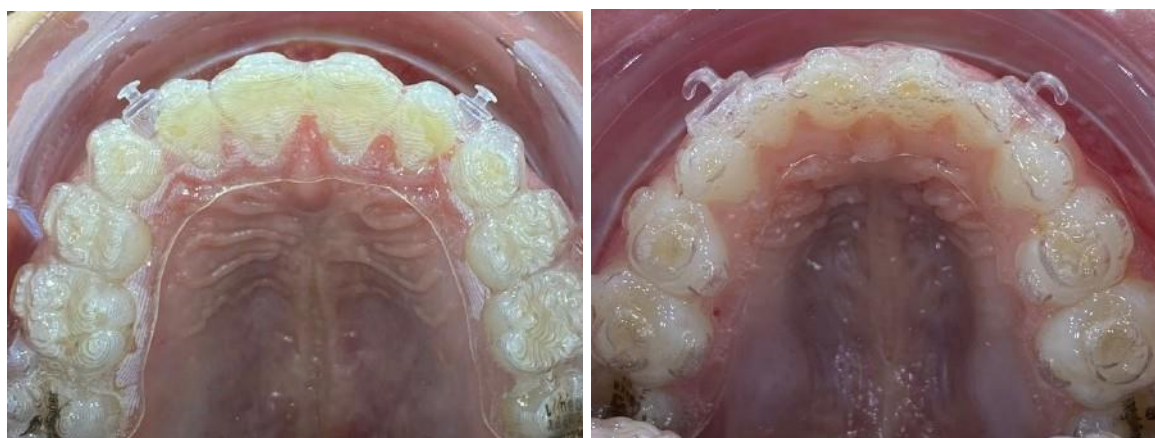

Figure 2: angel Button™ angel Hook™.

Material and Method

The purpose of the clinical case presented here is to demonstrate that early management of Class III malocclusions offers better results, and how the use of the protraction mask followed by maxillary orthopedic therapy is highly beneficial for these patients.

Maxillary expansion will be carried out using clear aligners, designed with a high cut-off line. These aligners will simulate the mass movements of rapid maxillary expansion (RME) without individual movements of

the upper arch teeth. For each stage of treatment, a set of two aligners will be used: the first (MASTER CONTROL S™), made of TUP+ PET-G material, will initiate movement due to its more flexible properties, while the second (MASTER CONTROL™), made of TPU, will consolidate movement due to its more rigid characteristics. Each aligner will be used for five days, for a total of ten days per phase. The magnitude of expansion in each stage will be 0.2 mm, and the total will vary according to the severity of the case (Figure 3).

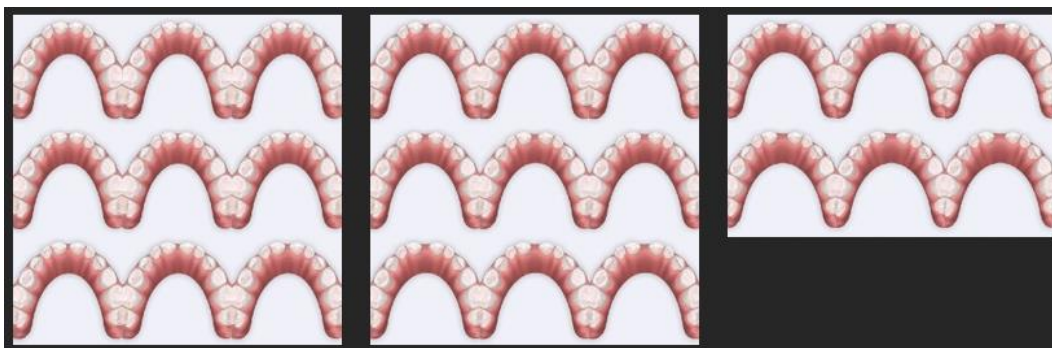


Figure 3: Procedure for palatal expansion using aligners

The aligners will be equipped with a button or hook placed between the lateral incisor and the primary canine, which will serve to connect the maxilla to the face mask stem Figure 2. The face mask has an adjustable anterior arch, which is used to apply traction on the maxilla using elastics. During maxillary expansion, elastics will be used to provide a force of 300-500 grams per side, and it is recommended that the mask be worn for an average of 12 hours per day (Figure 4).

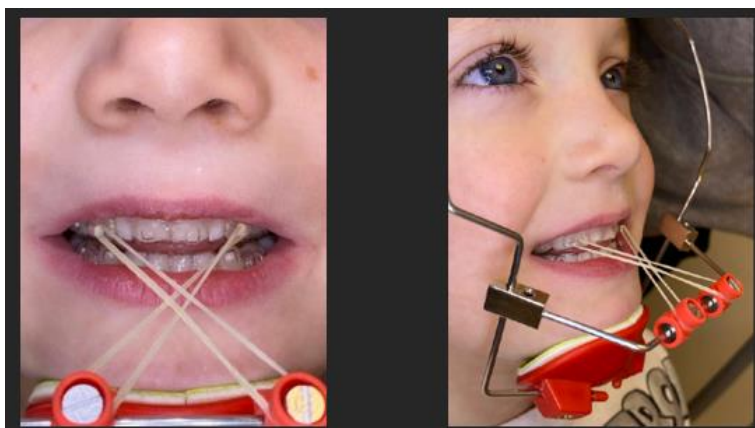

Figure 4: Facemask anchored to hooks integrated into the aligners.

The protocol described is designed to be applied to patients with primary dentition or erupting first molars. This makes it possible to take advantage of the first growth spurt, which occurs between 5 and 7 years of age. In this period, with the eruption of the first molars, it is possible to establish a new adequate occlusal plane, that favors mandibular movements and promoting optimal anteroposterior and vertical dynamics [56-60] (Figure 5).

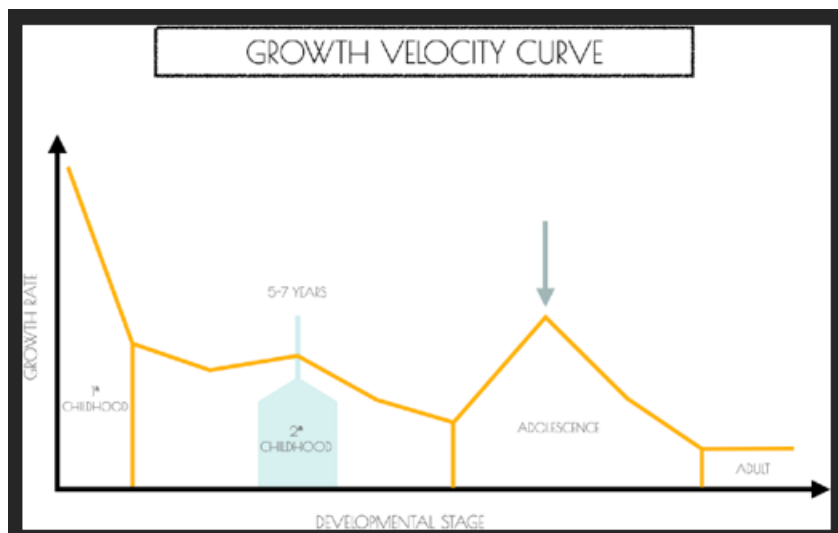


Figure 5: Growth Velocity Curve.

Clinical Case

Patient 4 years and 6 months

A patient aged 4 years and 6 months was referred for a general assessment for the first time to the dentist. The main reason for consultation was the presence of caries and parental concern about an apparent mandibular protrusion.

Diagnosis

On extraoral clinical examination (FIGURE 6), the patient presented an oval face with proportionate facial thirds, although with a slight increase in the lower third, mesofacial pattern and lip competence. There was a slight deviation of the chin to the left, with no significant asymmetry in the frontal plane. When smiling, 90% of the upper incisors and 70% of the lower incisors were present, with visible buccal corridors, symmetrical elevation of the commissures, and no gingival exposure when smiling. The profile was concave, with a favorable cervicomandibular angle and biretrochelism. In addition, adenoid facies features were observed, with mixed daytime and nocturnal breathing.

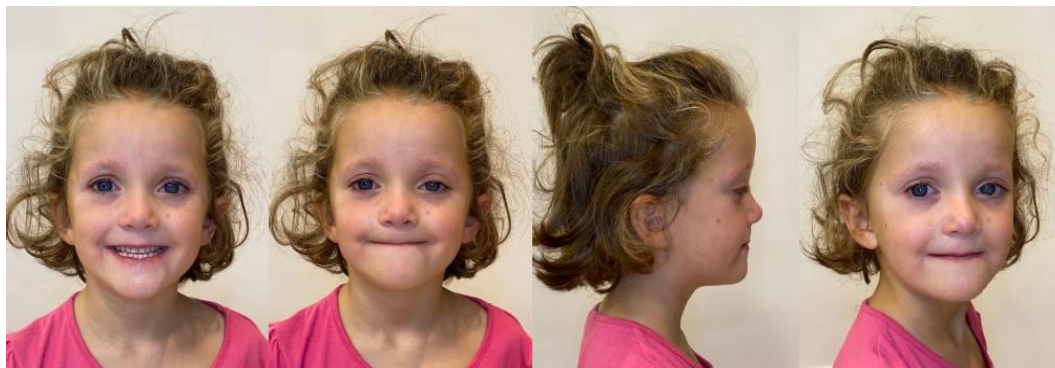

Figure 6: Facial Photographs Pre-Treatment

On intraoral examination (Figure 7), bilateral posterior crossbite and anterior edge-to-edge bite were observed. The midlines were centric and the lower one was deviated to the left in maximum occlusion due to a functional deviation. In the lateral photographs, on the right side there was a Class III molar and canine, almost complete and slightly more marked on the left side, coinciding with the mandibular functional deviation. In an occlusal view, the arches were parabolic, with lack of transversal development (skeletal cause of the upper) and absence of diastemas and primate spaces. The upper Wilson's curve was correct without coronal offsets and the lower Spee's curve was slightly accentuated.

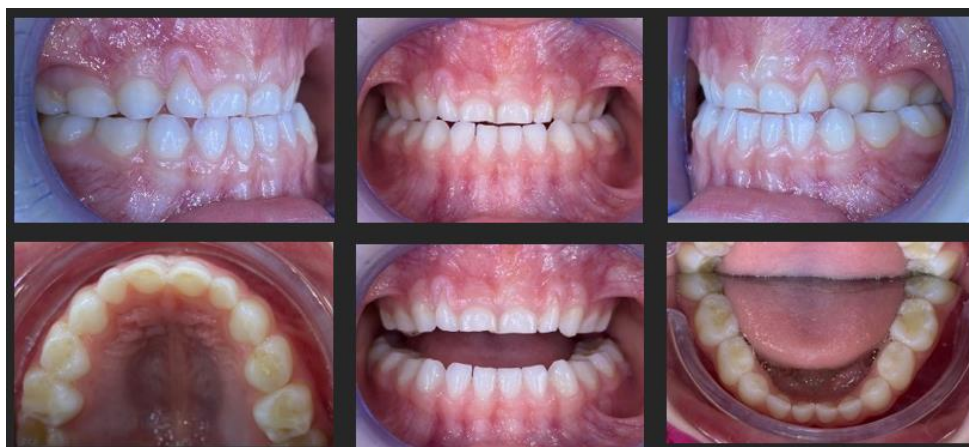

Figure 7: Intraoral Photographs Pre-Treatment

On functional examination, (Figure 8) the patient had mixed day and night breathing with a normal swallowing pattern, lip competence and a low tongue. The patient had no symptoms or signs of joint dysfunction. The functional Planas chewing angles were asymmetrical, the left side with propulsive gothic angles being smaller.

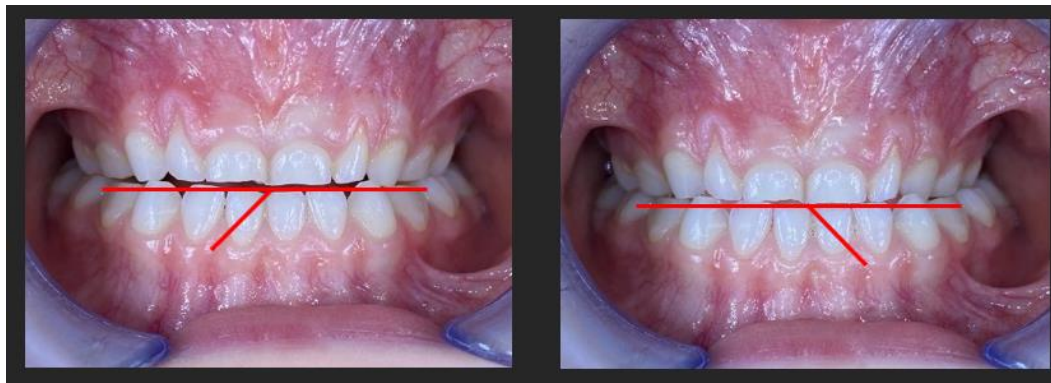


Figure 8: Mandibular Dynamics PreTreatment (Functional Masticatory Angle of Planas)

Radiographic examination (Figure 9) showed a Class III skeletal malocclusion (0° SNA) of maxillary cause (A-Np at -2.81), with the mandible basically well positioned (Poig-Np at -5) and with a mesodolicofacial pattern (Ar-Go'-Me of 131°). Symmetrical condyles and hypertrophic turbinates.

At the dental level, radiological crowding was observed, the first molars were in the process of eruption, the 36th molar was slightly present in the mouth. The upper incisor was retroinclined (Burstone 96°), while the lower incisor was well positioned (Tweed 90°) and the interincisor angle was increased (153°).

The patient had no clinical problems or chronic diseases that could interfere with orthodontic treatment.

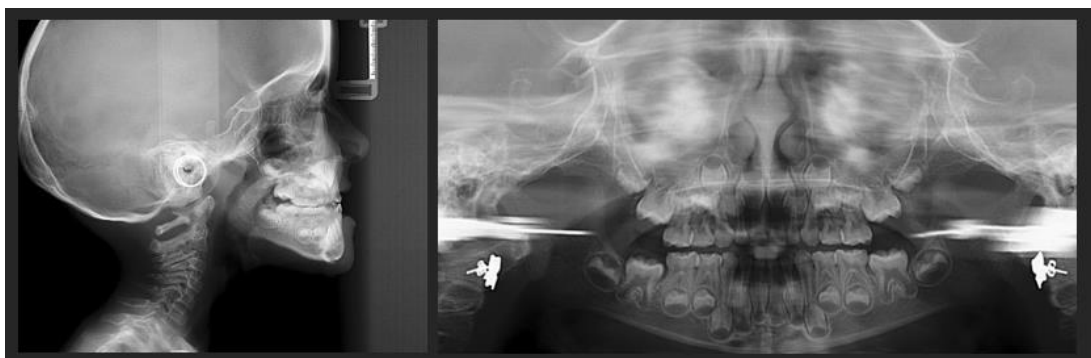

Figure 9: Pre-Treatment Radiographs

Objective

The treatment plan was designed as an initial phase of early orthodontic intervention, aimed at achieving dentoalveolar and skeletal goals through the combination of aligners and the use of a face mask. The objectives of this first phase, described in this article, include correction of posterior and anterior crossbite, modification of skeletal Class III by maxillary traction, promotion of a favorable change in the occlusal plane to optimize mandibular dynamics in the anterior-posterior and vertical planes, improvement of labial competence and obtaining a more harmonious soft facial profile. During this phase, a set of AngelAligner® aligners consisting of 26 stages (52 aligners) was used, with regular clinical check-ups every 60 days.

Results

Adherence to treatment by the patient was optimal, both in the use of the aligners and in the use of the facial mask. At the end of this first phase of treatment, a notable improvement in aesthetic balance was observed. At the extraoral level, adequate lip closure was achieved without muscular tension, accompanied by a more harmonious nasolabial angle. The patient's facial profile showed less concavity, with a more defined mentolabial angle and greater projection of the chin. The aesthetics of the smile improved considerably due to the maxillary protraction and the correction of the transverse discrepancy (Figure 10).



Figure 10: Facial Photographs Post-Treatment

Intraorally, the patient presented a bilateral molar and canine occlusion in slight class II (Figure 11). The bilateral posterior crossbite resolved correctly, as did the anterior crossbite. Both overbite and protrusion showed values within normal, and the midlines were overcorrected by modifying the functional angle on the left side, with the aim of altering the predominant chewing pattern that the patient had previously presented.

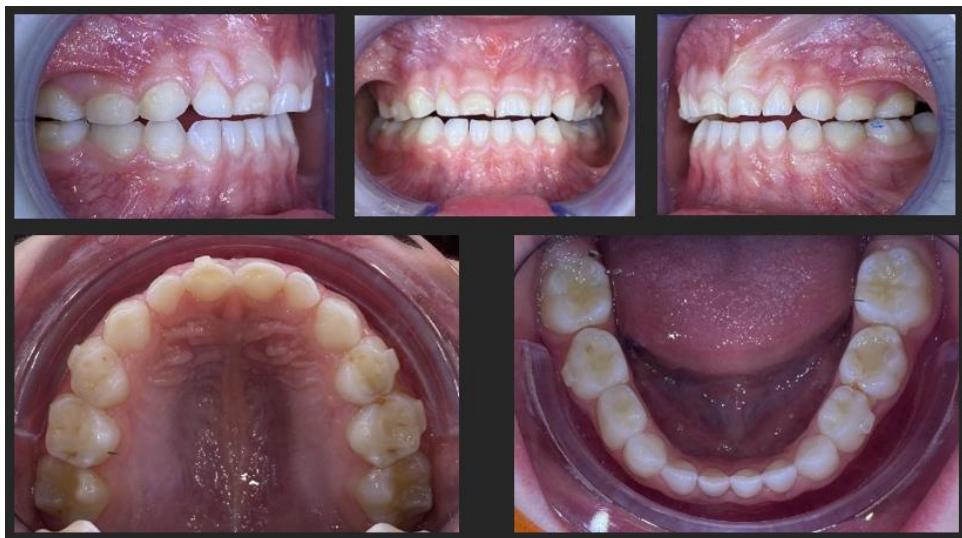

Figure 11: Intraoral Photographs Post-Treatment

From a functional point of view, the patient performed exercises focused on improving nasal breathing and correct placement of the tongue at rest on the palate. Masticatory function was balanced, achieving appropriate functional masticatory angles, with no evidence of mandibular propulsion (Figure 12).

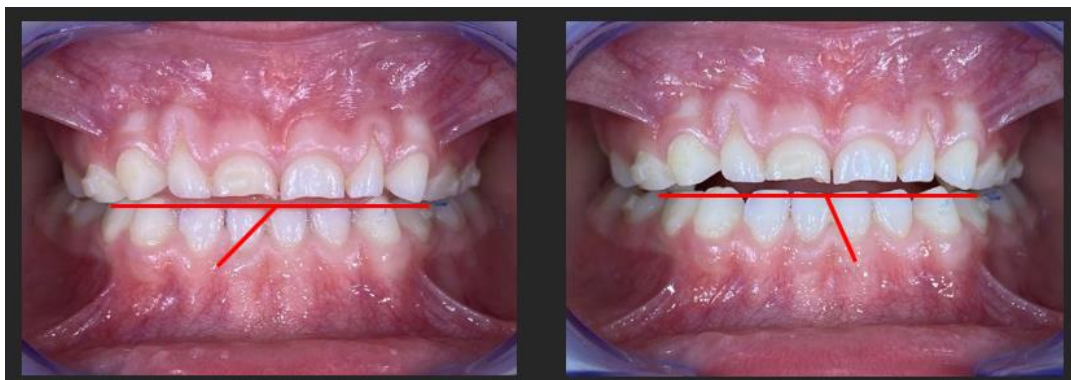


Figure 12: Mandibular Dynamics Post-Treatment (Functional Masticatory Angle of Planas)

As for the radiological evaluation, only one new lateral skull X-ray was performed due to the young age of the patient and the short interval between radiological recordings. The results indicated an increase in the SNA angle (from 74.26° to 76.91°), while the SNB angle remained stable (74.30° // 74.25°), resulting in a normal maxillary relationship (ANB = 2.77). Another significant change was the reduction in the Witts index from -3.3 to -1.13, evidencing anteroposterior harmonization. Vertical skeletal measurements remained constant, with no change in the Sn-Go-Gn angle (131°). In addition, the anterior vertical dimension decreased (ANS-Me from 53.18 to 50.72), thus achieving a more proportionate lower third. (Figure 13) The complete results are presented in Table 1.

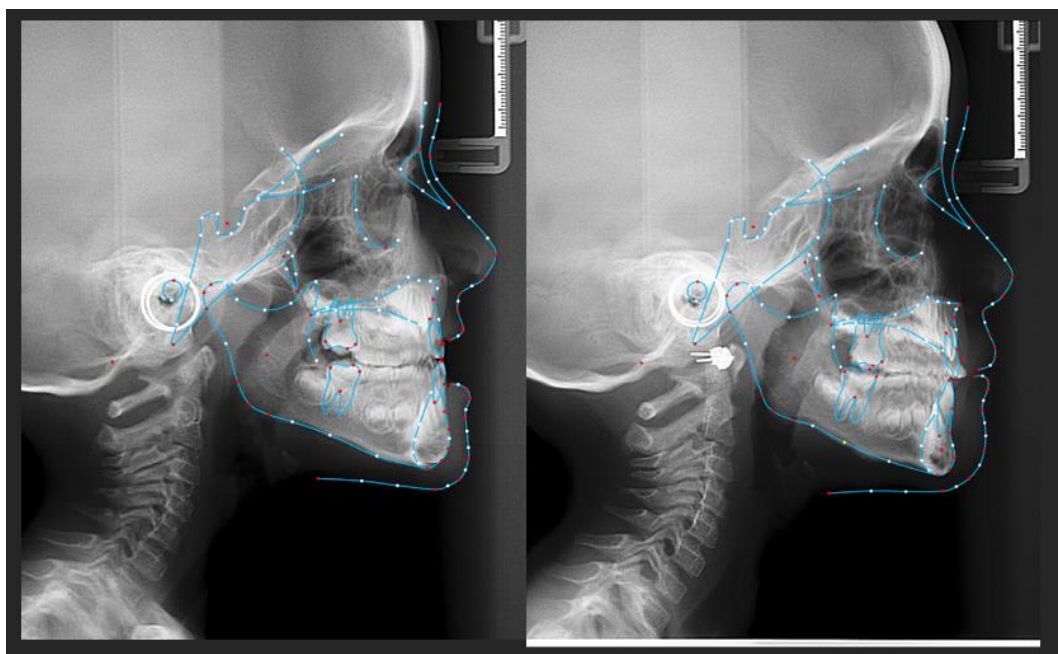


Figure 13: Pre and Post Treatment Cephalometry

CEPHALOMETRIC VARIABLES	PRE-TREATMENT	POST-TREATMENT
SNA (°)	74,26°	76,91°
SNB (°)	74,30°	74,25°
ANB	0	2,77
SNGoGn (°)	131°	131°
A-Np(mm)	-2,81	-0,6
Pog-Np(mm)	-5,11	-5,23
ANS-Me(mm)	53,18	50,72
Wits (mm)	-3,3	-1,13

Table 1: Pre and Post Treatment Cephalometric Data

Discussion

Several studies have shown the relevance of early treatment in patients with Class III malocclusion. In most cases with early mixed dentition or late deciduous dentition, the face mask is considered the standard therapeutic option [19-21]. This approach fully coincides with our strategy, which was based on maxillary traction with face mask to achieve skeletal protraction of the maxilla and redirect mandibular growth. In this case, the SNA angle increased from 74.26° to 76.91°, while the SNB remained constant at 74.25°, resulting in a normal maxillomandibular relationship with a final ANB of 2.77. Similarly, reported an average improvement of 4.1 mm in the Wits index using the Hybrid Hyrax combined with a face mask, although they noted that the skeletal effects would have been greater with earlier treatment [16]. In this case, a significant improvement in the Wits index was observed, from -3.3 mm to -1.13 mm. The literature that analyzes the effects of posteroanterior traction of the maxillary complex in Class III patients suggests that the improvement in sagittal intermaxillary skeletal relationships is often associated with an increase in inverted skeletal relationships, which may be detrimental, particularly in hyperdivergent Class III patients. However, recent studies indicate that vertical skeletal characteristics do not significantly affect short-term outcomes in expansion and face mask treatment [38]. In this case, vertical skeletal measurements showed no variation, with the Sn-Go-Gn angle remaining at 131°. Regarding transverse improvement using aligners, in their randomized controlled trial, observed a significant increase in palatal volume ($p < 0.05$) in both the aligner group (mean increase of $243.95 \pm 473.24 \text{ mm}^3$) and the rapid palatal expander (RPE) group (mean increase of $532.01 \pm 540.52 \text{ mm}^3$). No statistically significant differences ($p < 0.05$) were found in the variation from T0 to T1 between the aligner and RPE groups for all the evaluated outcomes, which aligns with the results obtained in our patient [45]. Upon completion of treatment with the facemask and aligners, the patient was retained with passive aligners, awaiting dental replacement.

Conclusion

- This clinical case illustrates the favorable evolution of early treatment of Class III malocclusion using a combined therapy of extraoral orthopedics and maxillary orthopedic appliances.

- Aligners have proven to be an effective tool in the early interceptive and orthopedic treatment of Class III malocclusions when used in combination with the facial mask.
- This therapeutic combination makes it possible to correct dentofacial alterations, taking advantage of the capacity of the aligners to guide dental movements while the facial mask favors skeletal correction.
- The success of the treatment relies to a large extent on an accurate diagnosis and the active collaboration of the patient and her family environment.

In conclusion, Class III malocclusion should be intercepted early, prioritizing growth redirection, especially when the maxilla is the main etiological factor or when dental and/or functional factors are involved. Diagnosis, therapeutic planning and prognosis depend on a number of characteristics that the orthodontist must carefully evaluate, such as the patient's age, growth potential and skeletal pattern. The earlier the intervention, the greater the likelihood of favorable responses in maxillary advancement and transverse expansion. Proper use of orthopedic devices, with correct application of force in terms of intensity and direction, together with patient adherence, are determining factors in achieving optimal results.

Conflict of interest Statement

Declaration of Interests: The authors have no conflicts of interest to declare.

Funding: The authors declared that this study has received no financial support.

Availability of data and materials: The authors declare that the materials are available. Ethics approval and consent to participate: The study was performed in accordance with the Declaration of Helsinki.

Consent for publication: Written informed consent was obtained from the patient for publication of this short report and any accompanying images.

Disclosure of interest: The authors declare that they have no competing interest.

References

1. Deguchi T and Kageyama T. (2014). Stability of Class III treatment strategies in growing patients: A systematic review of the literature. 151-178.
2. Oltramari PVP, Garib DG, Conti ACCF, Henriques JFC, Freitas MR. (2005) Orthopedical treatment of Class III in different facial patterns. R Dental Press Ortodon Ortop Facial. 10(5):72-82
3. Kapust AJ, Sinclair PM, Turley PK. (1998) Cephalometric effects of face mask/expansion therapy in Class III children: a comparison of three age groups. Am J Orthod Dentofacial Orthop. 113(2):204-12.
4. Lombardo EC, Franchi L, Lione R, Chiavaroli A, and Cozza P. et al. (2020) Evaluation of sagittal airway dimensions after face mask therapy with rapid maxillary expansion in Class III growing patients. International Journal of Pediatric Otorhinolaryngology. 130, 109-794.
5. Toffol LD, Pavoni C, Baccetti T, Franchi L, and Cozza P. (2008) Orthopedic treatment outcomes in Class III malocclusion. A systematic review. Angle Orthod. 78(3):561-73.
6. Arun T, Nalbantgil D, Sayinsu K. (2006) Orthodontic treatment protocol of Ehlers-Danlos syndrome type VI. Angle Orthod. 76(1):177-83
7. Cozzani G. (1981) Extraoral traction and class III treatment. Am J Orthod. 80(6):638-50
8. Chung JC. (2006) Redirecting the growth pattern with rapid maxillary expander and chin cup treatment: changing breathing pattern from oral to nasal. World J Orthod. 7(3):236-53.
9. González AM, Mendoza LP, Fuego MDCR, and Gutiérrez AG. (2016) Mordida cruzada anterior y tratamiento en la atención primaria. Revista de Ciencias Médicas de Pinar del Río. 20(4), 88-98.

10. Escalona EE, Navarro MBR, Rivera HO, Jose M, and Carreras JLM et al. (2011) Tratamiento temprano de las Clases III. *RevEspOrtod.* 79-89.
11. Hardy Dk, Cubas Yp, and Orellana MF. (2012) Prevalence of Angle Class III malocclusion: a systematic review and meta-analysis. *Open J Epidemiol.* 2, 75-82.
12. Kale B and Buyukcavus MH. (2020) Comparison of three-dimensional soft-tissue evaluations between skeletal and pseudo-class III malocclusions. *Sci Rep.* 10(1):14717-28.
13. Minase RA, Bhad WA, and Doshi UH. (2019) Effectiveness of reverse twin block with lip pads RME and face mask with RME in the early treatment of class III malocclusion. *Prog Orthod.* 20(1):14.
14. Williams S and Andersen CE (1986) The morphology of the potential class III skeletal pattern in the growing child. *Am J Orthod* 89(4): 302–311.
15. Jacobson A, Evans WG, Preston CB, and Sadowsky PL (1974) Mandibular prognathism. *Am J Orthod* 66(2):140–171.
16. Williams MD, Sarver DM, Sadowsky PL, Bradley E (1997) Combined rapid maxillary expansion and protraction facemask in the treatment of class III malocclusions in growing children: a prospective long-term study. *Semin Orthod* 3(4):265–274.
17. Ellis E 3rd, McNamara JA Jr (1984) Components of adult class III malocclusion. *J Oral Maxillofac Surg* 42(5):295–305.
18. Guyer EC, Ellis EE 3rd, McNamara JA Jr and Behrents RG (1986) Components of class III malocclusion in juveniles and adolescents. *Angle Orthod* 56(1):7–30.
19. Yagci A and Uysal T. (2010) Effect of modified and conventional facemask therapy on condylar position in Class III patients. *Orthod Craniofac Res.* 13(4):246-54.
20. Tsai HH. (2001) Components of anterior crossbite in the primary dentition. *ASDC J Dent Child.* 68(1):27-32, 10.
21. Saadia M and Torres E. (2000) Sagittal changes after maxillary protraction with expansion in Class III patients in the primary, mixed and late mixed dentitions: a longitudinal retrospective study. *Am J Orthod Dentofacial Orthop.* 117(6):669-80.
22. Uzuner, FD, Öztürk D, and Varlık SK. (2017). Effects of combined bonded maxillary expansion and face mask on dental arch length in patients with skeletal Class III malocclusions. *The Journal of Clinical Pediatric Dentistry.* 41, 75–81.
23. Auconi P, Scazzocchio M, Cozza P, McNamara J A Jr, and Franchi, L. (2015). Prediction of Class III treatment outcomes through orthodontic data mining. *European Journal of Orthodontics,* 37, 257–267.
24. Smith T, Ghoneima A, Stewart K, Liu S, and Eckert G et al. (2012) Three- dimensional computed tomography analysis of airway volume changes after rapid maxillary expansion. *Am J Orthod Dentofacial Orthop* 141(5):618-26.
25. Frankel R (1970) Maxillary retrusion in class 3 and treatment with the function corrector 3. *Rep Congr Eur Orthod Soc.* 249–259.
26. Frankel R (1971) Tooth eruption and alveolar process under the orthodontic effect of functional appliances. *Fortschr Kieferorthop* 32(2):217–228.
27. Clark WJ. *Twin Block Functional Therapy.* Mosby-Wolfe, London 1995.
28. Sakamoto T, Iwase I, Uka A and Nakamura S (1984) A roentgenocephalometric study of skeletal changes during and after chin cup treatment. *Am J Orthod* 85(4):341–350.
29. Thilander B (1965) Chin-cap treatment for angle class 3 malocclusion. *Rep Congr Eur Orthod Soc* 41:311–327.
30. McNamara JR, and Brudon WL (1993) Orthodontic and orthopedic treatment in the mixed dentition. *Mich, Ann Arbor.*
31. Delaire J (1971) Manufacture of the Borthopedic mask. *Rev Stomatol Chir Maxillofac* 72(5):579–82.

32. Petit H (1983) Introduction to the biomechanical study of the facial mask and its accessories. *Orthod Fr* 54(2):353–365.
33. McNamara JA Jr (1987) An orthopedic approach to the treatment of class III malocclusion in young patients. *J Clin Orthod* 21(9):598– 608
34. Nanda R (1980) Biomechanical and clinical considerations of a modified protraction headgear. *Am J Orthod* 78(2):125–139
35. Kim JH, Viana MA, Graber TM, Omerza FF and BeGole EA (1999) The effectiveness of protraction face mask therapy: a meta-analysis. *Am J Orthod Dentofacial Orthop* 115(6):675–685
36. Toffol LD, Pavoni C, Baccetti T, Franchi L, and Cozza P (2008) Orthopedic treatment outcomes in class III malocclusion. A systematic review. *Angle Orthod* 78(3):561–573.
37. Cordasco G, Matarese G, Rustico L, Fastuca S, and Caprioglio A et al. (2014) Efficacy of orthopedic treatment with protraction facemask on skeletal class III malocclusion: a systematic review and meta-analysis. *Orthod Craniofac Res* 17(3): 133–143
38. Akkaya S, Lorenzon S, Ucem TT (1999) A comparison of sagittal and vertical effects between bonded rapid and slow maxillary expansion procedures. *Eur J Orthod* 21(2):175–180.
39. Wertz RA (1970) Skeletal and dental changes accompanying rapid midpalatal suture opening. *Am J Orthod* 58(1):41–66.
40. Pangrazio-Kulbersh V, Berger J and Kersten G. (1998) Effects of protraction mechanics on the midface. *Am J Orthod Dentofacial Orthop* 114(5):484–491
41. Cozza P, Giancotti A and Petrosino A. (2001) Rapid palatal expansion in mixed dentition using a modified expander: a cephalometric investigation. *J Orthod* 28(2):129–134
42. Sarver DM and Johnston MW. (1989) Skeletal changes in vertical and anterior displacement of the maxilla with bonded rapid palatal expansion appliances. *Am J Orthod Dentofacial Orthop* 95(6):462– 466.
43. Liou EJ and Tsai WC. (2005) A new protocol for maxillary protraction in cleft patients: repetitive weekly protocol of alternate rapid maxillary expansions and constrictions. *Cleft Palate Craniofac J.* 42(2): 121–127.
44. Foersch M, Jacobs C, Wriedt S, Hechtner M and Wehrbein H. (2015) Effectiveness of maxillary protraction using facemask with or without maxillary expansion: a systematic review and meta- analysis. *Clin Oral Investig.* 19(6):1181-92.
45. Bruni A, Ferrillo M, Gallo V, Parrini S and Garino F. (2024) Castroflorio T, Deregibus A. Efficacy of clear aligners vs rapid palatal expanders on palatal volume and surface area in mixed dentition patients: A randomized controlled trial. *Am J Orthod Dentofacial Orthop.* 166(3):203-214.
46. Levrini L, Carganico A and Abbate L. (2021) Maxillary expansion with clear aligners in the mixed dentition: A preliminary study with Invisalign® First system. *Eur J Paediatr Dent.* 22(2):125-128.
47. Lione R, Lombardo EC, Paoloni V, Meuli S and Pavoni C et al. (2023) Upper arch dimensional changes with clear aligners in the early mixed dentition: A prospective study. *J Orofac Orthop.* 84(1):33-40.
48. Skaik A, Wei XL, Abusamak I and Iddi I. (2019) Effects of time and clear aligner removal frequency on the force delivered by different polyethylene terephthalate glycol-modified materials determined with thin-film pressure sensors. *Am J Orthod Dentofacial Orthop.* 155(1):98-107.
49. Tartaglia GM, Mapelli A, Maspero C, Santaniello T and Serafin M et al. (2021) Direct 3D Printing of Clear Orthodontic Aligners: Current State and Future Possibilities. *Materials (Basel).* 14(7):1799.
50. Lümckemann N, Klimenta M, Hoffmann M, Meinen J and Stawarczyk B (2023). Dimensional Stability and Reproducibility of Varying FFF Models for Aligners in Comparison to Plaster Models. *Materials (Basel).* 16(13):4835.
51. Elkholly F, Schmidt S, Schmidt F, Amirkhani M and Lapatki BG. (2023) Force decay of polyethylene terephthalate glycol aligner materials during simulation of typical clinical loading/unloading scenarios. *J Orofac Orthop.* 84(3):189-201.

52. Iijima M, Kohda N, Kawaguchi K, Muguruma T and Ohta M. (2015) Naganishi A, Murakami T, Mizoguchi I. Effects of temperature changes and stress loading on the mechanical and shape memory properties of thermoplastic materials with different glass transition behaviours and crystal structures. *Eur J Orthod.* 37(6):665-70.
53. Lyu X, Cao X, Yan J, Zeng R and Tan J. (2023) Biomechanical effects of clear aligners with different thicknesses and gingival-margin morphology for appliance design optimization. *Am J Orthod Dentofacial Orthop.* 164(2):239-252.
54. Elshazly TM, Keilig L, Salvatori D, Chavanne P and Aldesoki M. (2022) Effect of trimming line design and edge extension of orthodontic aligners on force transmission: An in vitro study. *J Dent.* 125:104276.
55. González Zamora D, Vignolo Lobato R, Pérez Reátegui P, Fernández Alonso A, Cámara Rivera M. (2023) Innovaciones en el tratamiento con alineadores transparentes. *Ortod. Esp.* 61 (3); 21-45.
56. Jean-Louis Raymond. (2021) *Orthodontie systémique: diagnostic et traitement.* France: Editorial.
57. Jean-Louis Raymond. (2022) Le diagnostic systémique. *L'Orthodontie Française.* 93(1):7-18
58. Jean-Louis Raymond. (2023) *Orthopedie Systémique des Classes III.* France: Editorial.
59. Raymond JL, Pimentel I and Vignolo R. (2009) Tratamiento ortopédico de las maloclusiones de clase III: masticación y plano oclusal. *Ortodoncia Clínica.* 12(4):186-93
60. Jean-Louis Raymond, Kolf, J (Co-auteur). (2014) Complexité système masticateur: manifeste pour un nouveau paradigme de l'occlusion dentaire. France: Editorial.