

## Customized Mandibular Reconstruction in an 8-Year-Old with Juvenile Ossifying Fibroma: A Case Report Using a Growth-Adaptable Titanium Implant

**Abdul Hameed Attar<sup>1</sup>, Ehtaih Sham<sup>2</sup>, Satyajit Wadje<sup>3</sup> and Rui Coelho<sup>4</sup>**

<sup>1</sup>Maxillofacial Surgery Head of Department, Department of Faciomaxillary and Dental Surgery, Wockhardt hospital Mira Road Mumbai, India

<sup>2</sup>Professor Unit Head, Department of Faciomaxillary & Reconstructive Surgery, Vydehi institute of Medical & Dental Sciences, Bangalore

<sup>3</sup>Director at Braces & Faces Superspeciality Dental Care 3rd floor, 301, Commercial Complex, ROSE ICON, Pimple Saudagar, Pune, Pimpri-Chinchwad, Maharashtra 411027

<sup>4</sup>Clinical Advisor for Plastic and Maxillofacial Surgery, Director of Bone easy Research Center

\***Corresponding author:** Rui Coelho, Clinical Advisor for Plastic and Maxillofacial Surgery, Director of Bone easy Research Center

**Citation:** Attar AH, Sham E, Wadje S and Coelho R. (2024) Customized Mandibular Reconstruction in an 8-Year-Old with Juvenile Ossifying Fibroma: A Case Report Using a Growth-Adaptable Titanium Implant. *Genesis J Surg Med.* 3(1):1-3.

**Received:** September 09, 2024 | **Published:** September 25, 2024

**Copyright**© 2024 genesis pub by Attar AH, et al. CC BY-NC-ND 4.0 DEED. This is an open-access article distributed under the terms of the Creative Commons Attribution-Non Commercial-No Derivatives 4.0 International License., This allows others distribute, remix, tweak, and build upon the work, even commercially, as long as they credit the authors for the original creation.

### Abstract

Juvenile ossifying fibroma (JOF) is a rare benign fibro-osseous tumor that predominantly affects the craniofacial bones in children and adolescents. This clinical case study focuses on an 8-year-old girl from India diagnosed with JOF of the mandible, necessitating a mandibulectomy. Initial reconstruction was performed using a fibula free flap. Six weeks post-surgery, the flap showed signs of necrosis, prompting an innovative solution: the development of a patient-specific implant designed to accommodate facial growth. The implant was fabricated using advanced

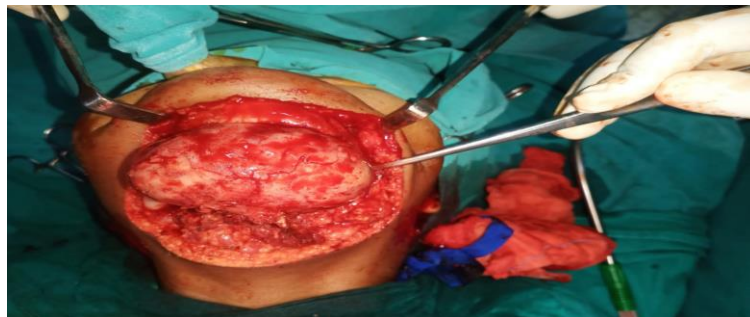
CT imaging, CAD design, and selective laser melting (SLM) techniques with Ti6Al4V titanium alloy, incorporating a sliding mechanism to allow for expansion as the patient matures. Follow-up over three years demonstrated successful integration of the implant, with no complications or signs of infection. The implant is planned for replacement upon reaching adulthood with a prosthesis that includes teeth connections.

## Introduction

Juvenile ossifying fibroma (JOF) is a rare, benign fibro-osseous tumor characterized by the replacement of normal bone with fibrous tissue and immature bone formation. Typically affecting the craniofacial skeleton of children and young adults, JOF often presents as a painless swelling, which can lead to significant facial asymmetry. Surgical resection is the mainstay of treatment, aiming to prevent further complications and restore aesthetics and function. However, in pediatric patients, mandibular reconstruction poses unique challenges due to ongoing craniofacial growth, which must be accommodated to avoid future deformities.

In this case, an 8-year-old girl from India was diagnosed with mandibular JOF and underwent a mandibulectomy followed by reconstruction with a fibula free flap. Although fibula grafts are commonly used in adults due to their structural support and vascularization, they pose limitations in children. Grafts may not grow proportionally with the developing mandible, risking functional impairments and facial asymmetry. In this case, the initial reconstruction failed due to flap necrosis.

Considering the patient's age and the risks of using a contralateral fibula—particularly the impact on limb growth and the potential for graft failure—the clinical team opted for an alternative solution. A patient-specific, custom titanium implant was designed to accommodate future mandibular growth. This approach prioritized preserving the patient's developmental trajectory and functional outcomes, avoiding further risks associated with autografts 1-3,9,10-13.



**Figure: 1** Juvenile Ossifying fibroma before removal

## Case Presentation

The patient, an 8-year-old girl of Indian origin, presented with a progressive swelling of the mandible. Radiographic and histopathological examinations confirmed the diagnosis of juvenile ossifying fibroma. A mandibulectomy was performed to excise the tumor, followed by immediate reconstruction using a fibula free flap. Despite initial success, the flap showed signs of necrosis six weeks postoperatively, indicating the need for a secondary intervention. To address this complication, a custom-made implant was planned to maintain the integrity of facial tissues and accommodate growth (4,5,6,7).

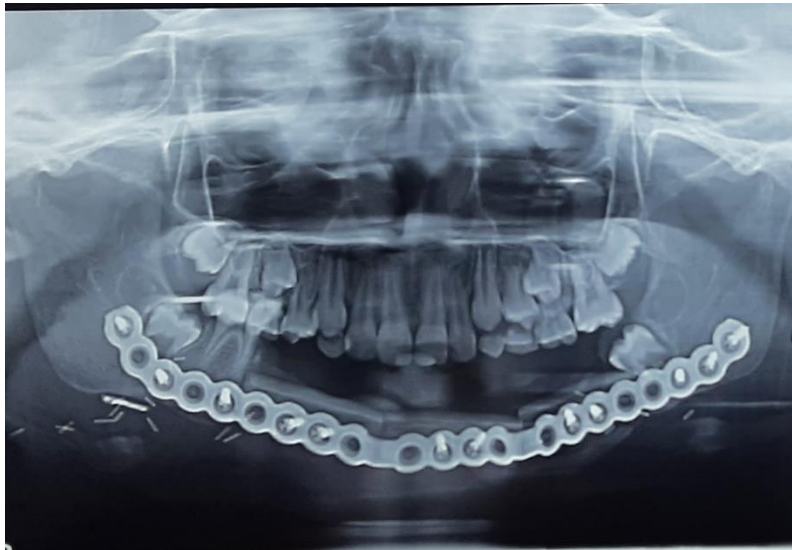


Figure: 2 Xray of the fibula flap

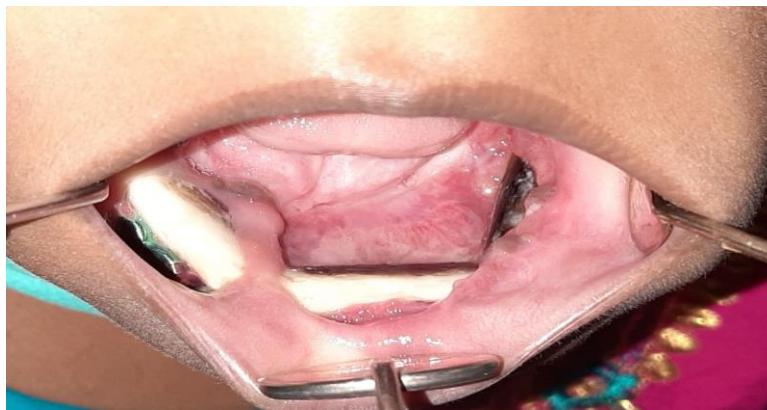

Figure: 3 Necrosis of the micro vascularized flap

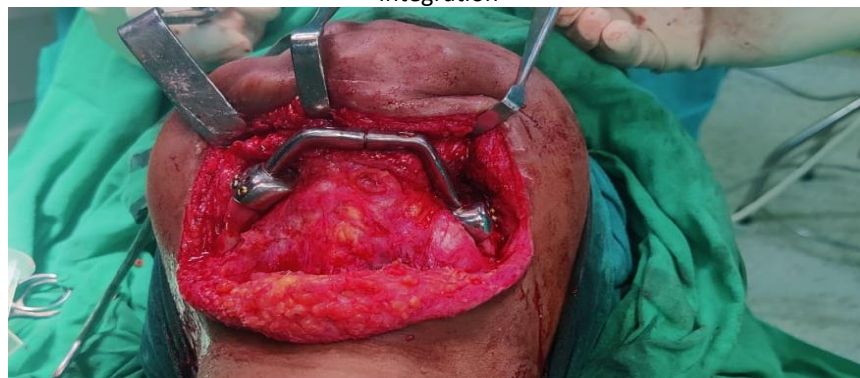
## Materials and Methods

The implant was made, planned and designed by Boneeasy company with supervision of the surgeons. The innovative reconstructive strategy involved the creation of a patient-specific implant using advanced imaging and manufacturing techniques:

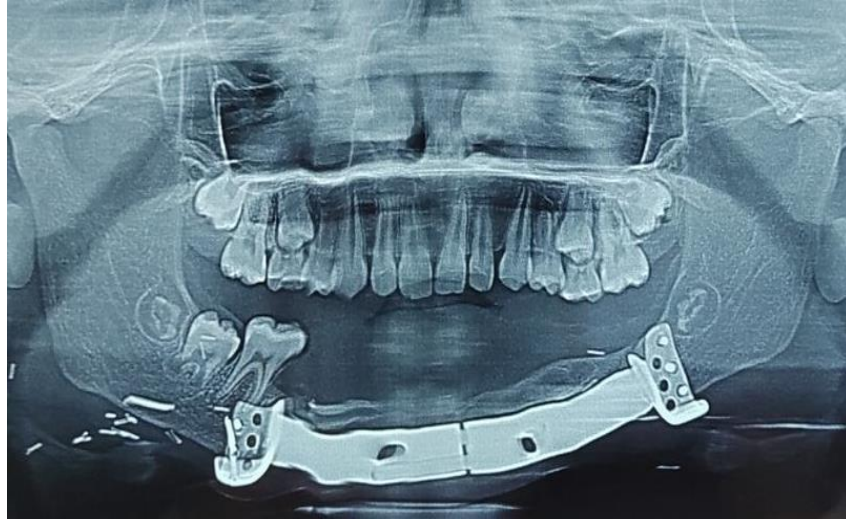
1. **CT Imaging and Segmentation:** A detailed CT scan of the patient's craniofacial structure was performed. The images were used to generate a three-dimensional model of the mandible, capturing the anatomy with precision.
2. **3D modeling and design:** Using CAD software, specifically Blender, the three-dimensional model was segmented to create an STL file. This file served as the blueprint for the design of the implant.
3. **Manufacturing:** The implant was produced using selective laser melting (SLM) for the initial rough structure, followed by refinement using a 3-axis milling center to incorporate a mechanical sliding component. The implant was fabricated using Ti6Al4V titanium alloy, known for its biocompatibility and strength. This sliding feature allowed the implant to expand, accommodating the natural growth of the patient's face.
4. **Finishing and Sterilization:** The entire device was polished to a mirror-like finish to minimize tissue irritation and was sterilized using ethylene oxide (ETO) to ensure patient safety.



**Figure: 4** Device manufactured with a sliding system to allow growth, and openings to allow tissue and muscle integration



**Figure: 5** Insertion and fixation of the custom device



**Figure: 6** One year follow up Xray showing the the stability of the device

### **Surgical Procedure**

The second surgery involved the removal of the necrotic fibula bone segments and the initial titanium plate. The custom implant was positioned in the remaining portion of the mandibular ramus, fixed securely in the closed position. The surgical approach utilized the existing submandibular scar from the initial operation, minimizing additional facial scarring. The implant's sliding mechanism was designed to permit controlled expansion, supporting the patient's facial growth over time.

### **Post-operative Care and Monitoring**

Following the surgery, the patient was closely monitored for any signs of complications, such as infection or implant displacement. Regular imaging was conducted to assess the integration of the implant and to monitor the growth of the mandible. The patient was also enrolled in a physiotherapy program to support her recovery and ensure the restoration of normal jaw function.

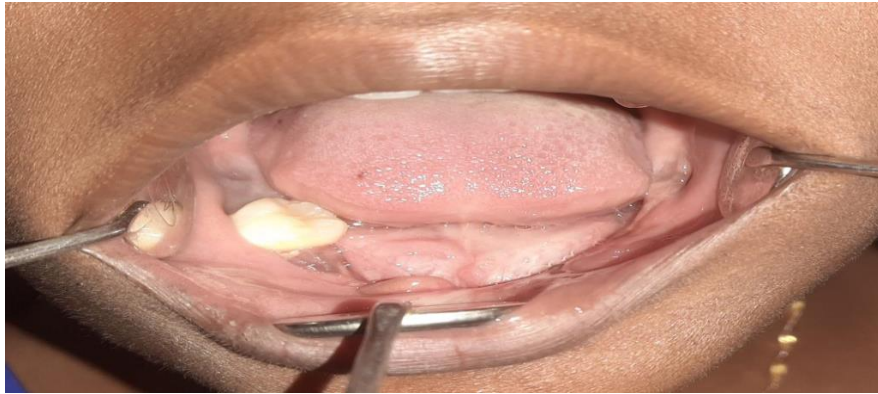### **Outcomes and follow-up**

**Immediate Post-Operative Results.** The immediate postoperative period was uneventful, with the patient showing good healing and no signs of infection. The implant maintained the mandibular contour, and the patient was able to resume a soft diet within a few weeks.

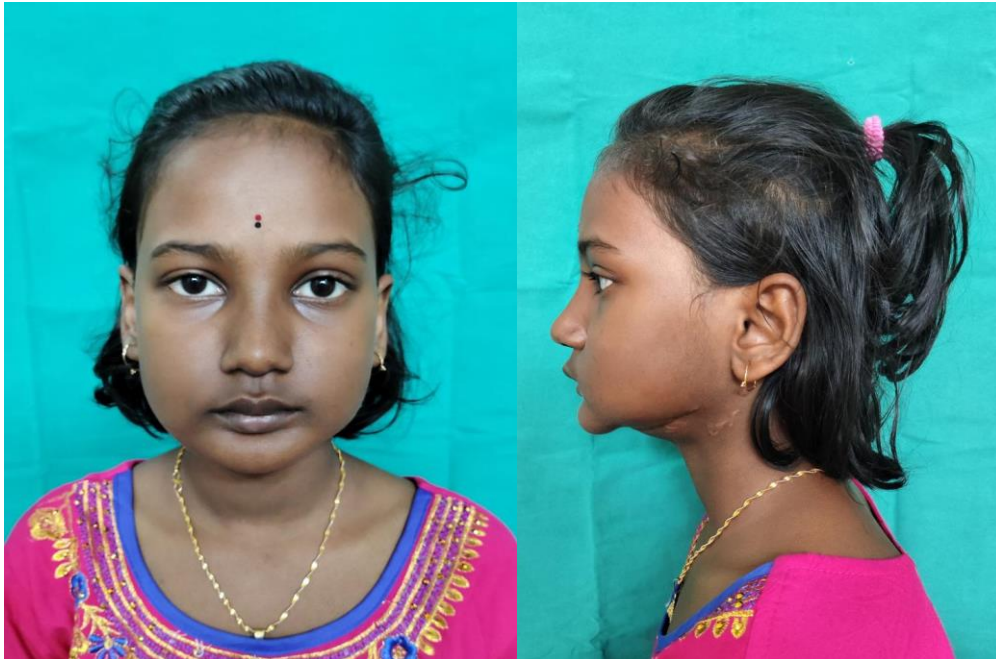**Long-Term Follow-Up: Growth Patterns and Implant Performance.** Over the following months, the patient was monitored through regular clinic visits and imaging studies. The implant performed well, maintaining its position and allowing for the natural growth of the mandible. The surrounding bone began to remodel around the implant, indicating good biological compatibility.

**Challenges and solutions encountered during follow-up:** Some challenges arose during follow-up, including minor adjustments to the implant to accommodate changes in the patient's growth. These adjustments were made non-invasively using external devices, such as orthodontic appliances, to guide the growth and ensure the mandible developed symmetrically.

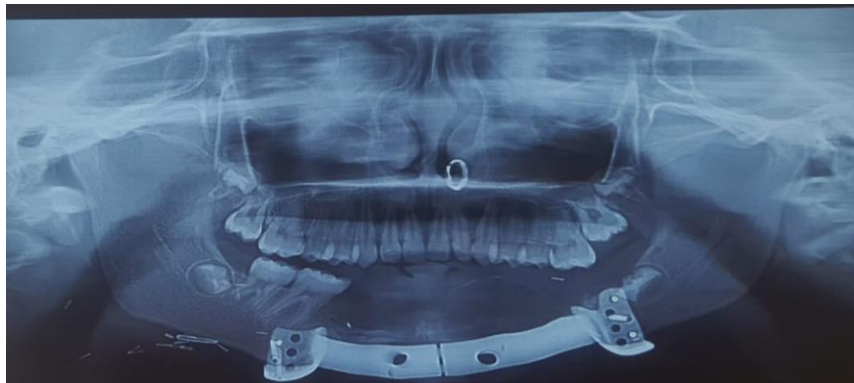




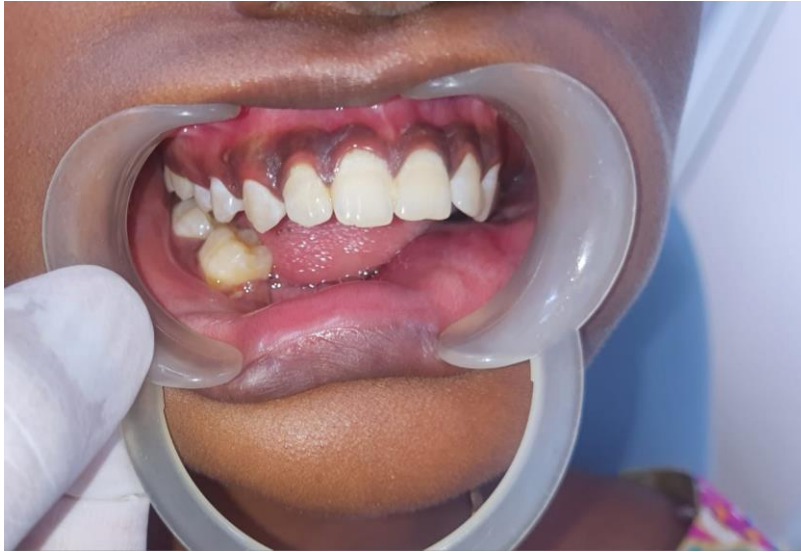**Figure: 7** One year follow up intra oral aspect



**Figure: 8** External aspect one year follow up



**Figure: 9** Follow up third year



**Figure: 10** Intra oral aspect third year



**Figure: 11** External aspect of third year follow up

## Discussion

**Comparison with Traditional Reconstruction Methods.** Traditional methods of mandibular reconstruction, such as the use of autografts or alloplastic materials, often fall short in pediatric patients due to the complexities of growth and development. This case illustrates the limitations of these methods and the need for alternative approaches in growing children.

**Advantages and Limitations of the Custom 3D-Printed Implant:** The use of a custom 3D-printed implant offers several advantages:

**Customization:** The implant was tailored to the patient's anatomy, ensuring a perfect fit and reducing the risk of complications.

**Growth accommodation:** The implant was designed to allow for continued mandibular growth, addressing one of the primary challenges in pediatric reconstruction. **Minimally Invasive:** The procedure avoided the need for additional autografts, reducing the risk of donor site morbidity.

However, there are limitations to this approach, including the need for ongoing monitoring and potential challenges in managing implant-related complications over time. Additionally, the long-term success of this approach in other patients remains to be seen, as this is still an emerging field of study.

**Potential Implications for Future Pediatric Mandibular Reconstructions** This case sets a precedent for the use of 3D printing technology in pediatric craniofacial surgery. The ability to create custom implants that accommodate growth could revolutionize the approach to complex reconstructions in children, providing better outcomes and reducing the need for multiple surgeries [3].

## Conclusion

The treatment of mandibular juvenile ossifying fibroma in pediatric patients presents significant challenges due to the need to accommodate ongoing growth. This case demonstrates the effectiveness of a custom-manufactured Ti6Al4V titanium implant with a sliding mechanism to allow for natural facial development. The innovative use of CT imaging, CAD modeling, and advanced manufacturing techniques resulted in successful reconstruction, with excellent functional and aesthetic outcomes over a three-year follow-up period.

## References

1. El-Mofty S. (2014) Fibro-osseous lesions of the craniofacial skeleton: An update. *Head and Neck Pathol.* 8(4):432-44.
2. Johnson LC. (1971) Juvenile ossifying fibroma of the maxilla. *Cancer.* 27(5):1120-31.
3. Carlson ER, Marx RE. (2021) The Mandible: Anatomy and Structural Architecture." *Oral Maxillofac Surg Clinics of North America.* 33(1):1-16.
4. Reid RR. (2011) Long-term outcomes of vascularized fibula free flap reconstruction for oromandibular defects. *Plastic and Reconstruct Surg.* 127(2): 1100-1107.
5. Taylor GI, Miller GDH, Ham FJ. (1975) The free vascularized fibula graft: a clinical extension of microvascular techniques. *Plastic Reconstruct Surg.* 55(5):533-544.
6. Kokosis, G. (2017) Vascularized fibula flap in head and neck reconstruction: A systematic review and meta-analysis. *J Craniofac Surg.* 28(6):1610-16.
7. Puricelli E, Chem RC. (2023) Thirty-eight-year follow-up of the first patient of mandibular reconstruction with free vascularized fibula flap. *Head Face Med.* 17(1):46.
8. Petrovic V, Harhaji M, Janjić Z. (2021) Clinical application of customized titanium implants in craniomaxillofacial surgery." *Front Surg.* 8:693719.
9. Bidra AS. (2016) Three-dimensional printing in complex craniomaxillofacial reconstruction and implant surgery. *J Prosth Dent.* 116(2):309-13.
10. Succo G. (2021) Principles of mandibular reconstruction after tumor resection. *Oral Oncology.* 123:105615.
11. Ângelo DF, Ferreira JRV. (2020) The Role of Custom-made Subperiosteal Implants for Rehabilitation of Atrophic Jaws - A Case Report. *Ann Maxillofac Surg.* 10(2):507-11.



12. Santos LMM, Figueiredo JLT, Coelho RPLM, Carvalho SDG, Martins MI. (2024) Comparison of Zygomatic Implants and Implantize Compact from Bone easy: A Finite Element Analysis for Bending and Safety Factor. *J Oral Med Dent Res.* 5(3):1-9.
13. Santos LMM, Ciloto BHA, Figueiredo JLT, Coelho RPLM. (2024) Analyzing the Forces on Dental Implant with Exclusive Apical Fixation: A Critical Evaluation of Leverage and ISO 14801/2016 Testing Protocols. *J Oral Med Dent Res.* 5(3):1-9.