

# Journal of Oral Medicine and Dental Research

Genesis-JOMDR-5(2)-60  
Volume 5 | Issue 2  
Open Access  
ISSN: 2583-4061

## Recent Advances in Digital Diagnosis of Caries

**Geeta IB<sup>1\*</sup> and Rachana G<sup>2</sup>**

<sup>1</sup>Professor. Dept of Conservative Dentistry and Endodontic, Rajarajeshwari Dental college and Hospital. Bangalore. Karnataka

<sup>2</sup>Postgraduate. Dept of Conservative Dentistry and Endodontics. Rajarajeshwari Dental college and Hospital. Bangalore. Karnataka

\***Corresponding author:** Geeta Sanjeev, Professor. Dept of Conservative Dentistry and Endodontic, Rajarajeshwari Dental college and Hospital. Bangalore. Karnataka.

**Citation:** Geeta, Rachana G. Recent Advances in Digital Diagnosis of Caries. J Oral Med and Dent Res. 5(2):1-7.

**Received:** July 02, 2024 | **Published:** July 14, 2024

**Copyright**© 2024 genesis pub by Geeta IB, et al. CC BY-NC-ND 4.0 DEED. This is an open-access article distributed under the terms of the Creative Commons Attribution-Non Commercial-No Derivatives 4.0 International License. This allows others distribute, remix, tweak, and build upon the work, even commercially, as long as they credit the authors for the original creation.

### Abstract

The dental caries is a multifactorial microbial disease of the hard structure of teeth, which results in localized demineralization of the inorganic portion and destruction of organic substance of the tooth. In recent years we can see an increase in research activity surrounding diagnostic methods, particularly in assessment of caries lesion. The recent advances in the digital diagnostic technologies have more advantages in detection of caries. caries. This review helps in providing an overview of digital diagnostic aids in detection of caries at initial stage.

### Keywords

Digital diagnostic aids; Incipient carious lesion

## Introduction

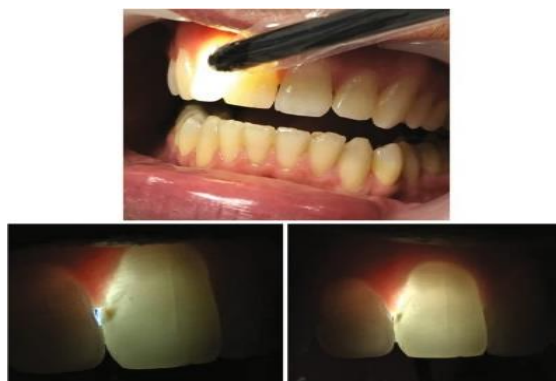Dental caries is a transmissible bacterial disease process caused by acids from bacterial metabolism diffusing into enamel and dentin dissolving the mineral. The bacteria responsible produce organic acids as a by-product of their metabolism of fermentable carbohydrates [1]. Undetected initial caries may later developed into deep carious lesion. Therefore, research in the field should be focused on early and accurate detection of incipient caries [2].

## Based on Illumination Methods

1. Fibre optic transillumination (FOTI)
2. Wavelength dependent FOTI
3. Digital imaging FOTI (DIFOTI)
4. Quantitative light induced fluorescence
- 5.

### Fibre Optic Transillumination (FOTI)

1. It acts on phenomenon of light scattering.
2. Sound enamel is composed of modified hydroxyapatite crystals, producing transparent structure.
3. This mainly works on different index of light transmission for decay, sound tooth enamel and dentin.

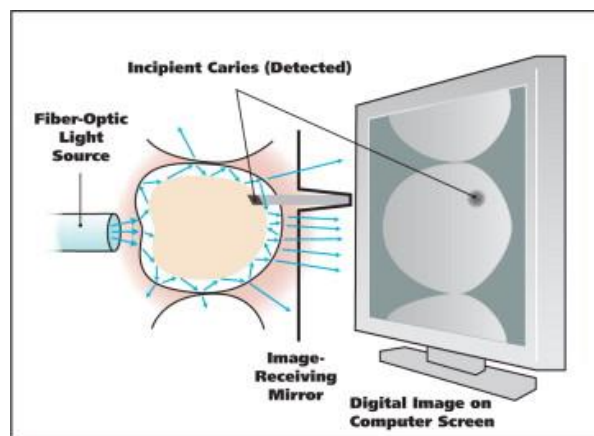


### Wavelength Dependent FOTI

- In incipient white-spot lesions, mineral loss is accompanied by increase in light scattering.
- In older discoloured lesions, light absorption is enhanced.
- Vaarkamp et al. observed that wavelength dependent light propagation through carious tissues can be used for the detection of the caries.

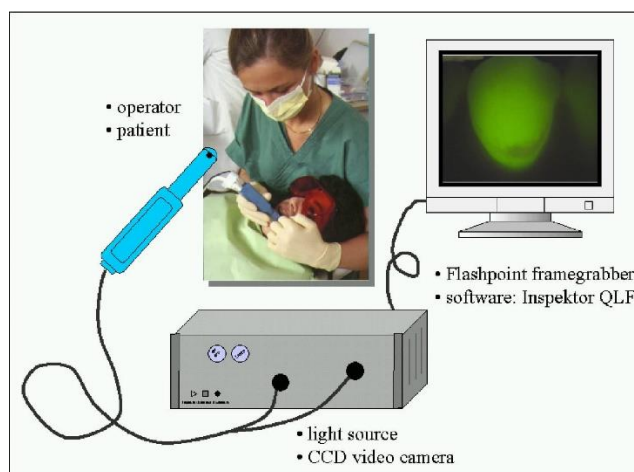
### Digital Imaging FOTI (DIFOTI)

1. This is combination of FOTI and digital ccd camera.
2. It uses safe whitelight, images are digitally captured using digital ccd and it will be analysed in computer.



### Quantitative Light Induced Fluorescence

1. The fluorescence for detection of caries was first introduced by Benedic in 1929.
2. It helps in early detection of caries.
3. This is suitable method for assessment of early enamel lesions in visually inaccessible areas.
4. Lesion area, depth and volume can be determined.



### Based on Laser Light

1. Diagnodent
2. Dye enhanced laser fluorescence technique (DELFT)
3. Diagnodent pen


### Diagnodent

1. First introduced in 1998
2. It uses simple laser diode.
3. This works on specific wave length where healthy tooth structure exhibits little or no fluorescence and carious tooth exhibits elevated readings on display.



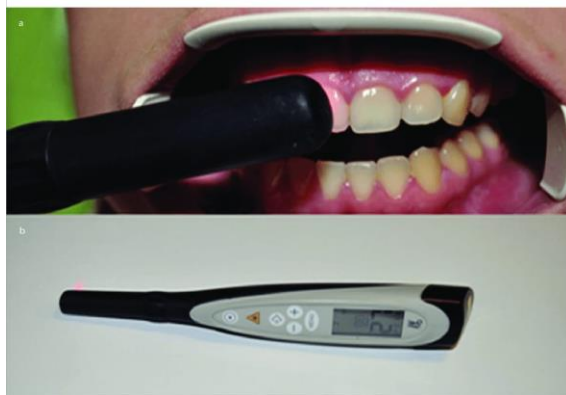### Dye Enhanced Laser Fluorescence Technique (DELFT)

1. It uses dyes with wavelength close to spectrum of diagnodent laser.
2. Based on dye penetration into carious lesion and it enhances detection by diagnodent laser.



### Diagnodent Pen

1. Advancement of diagnodent
2. It detects fissure and smooth surface caries accurately
3. Easy and quick to use.



## Based on Using Electric Current

### Electric Caries Monitor

1. This technique is based on electrical conductivity differences between sound and carious dentinal structure.
2. High values indicated well mineralized tissue where as high values indicates demineralized tissue.



## Endoscopy

1. Endoscopically viewed filtered fluorescence (EFF)
2. White light fluorescence
3. Videoscope
- 4.

### Endoscopically Viewed Filtered Fluorescence

1. In this technique it utilizes the fluorescence of enamel that will occur when it is illuminated with wavelength of 499-500nm.
2. White spot lesions appears darker than the sound enamel when the tooth is visualized under specific green filter number 58, attached to eyepiece.
3. This method have shown high sensitive for occlusal caries.

## White Light Fluorescence

1. Teeth is viewed without filter, white light is connected to endoscope with the help of fibre optic cable.

## Videoscope

1. Combined unit of both camera and endoscope is known as videoscope.
2. Direct view of surface can be seen on the screen
3. It provides magnified image.

## Radiography

1. Digital imaging radiography
2. Subtraction radiography
3. Computed tomography (CT)
4. X-ray microtomography
5. Transverse microradiography (TMR)
6. Tuned aperture CT (TACT)

## Digital Imaging Radiography

1. Digital radiography is a form of radiography that uses x-ray sensitive plates to capture data and then immediately transferring it to a computer system without any use of cassette.
2. Abesi et al stated that there is no significant difference between digital and conventional radiographic modalities in detection of non cavitated interproximal caries.
3. The important advancement was introduction of caries detection software (Logican Caries Detector Software) for assisting interproximal caries.

## Subtraction Radiography

1. Subtraction radiography offers great visualization of radiographic changes between a pair of radiographs by subtracting out the unchanging background distractions.
2. It improves diagnosis and treatment planning.
3. Valizadeh et al showed that digital subtraction images have potential to measure depth of proximal caries.

## Computed Tomography

1. It was introduced by Hounsfield in 1973.
2. It is three dimensional imaging.
3. Young et al. stated that dentists were able to detect dentinal proximal surface caries using high resolution CBCT images.

## X-ray Mirotomography

1. It is a shortened version of computerized axial tomography with high resolution.
2. Uses x-ray to create cross sections of a 3D object and then later to recreate a virtual model.

## Transverse Microradiography

1. This method is currently accepted gold standard for measurement of mineral loss in carious lesions.
2. It is widely accepted method to assess demineralization of dental hard tissue.
3. It is used to quantifying the mineral density in enamel carious lesion.

## Tuned Aperture CT

1. Based on the principles of tomosynthesis
2. It is series of radiographs taken from different angulations.
3. Low cost and 3D imaging system.
4. Soft ware stacks the basic images and reconstruct onto multiplanar images.

## Conclusion

Advanced diagnostic techniques play a very important role in diagnosis, data collection and assessing the condition and the utilizing of the information obtained. Diagnostic modalities available to clinicians to expand greatly on the foundation of a comprehensive visual assessment, which has been and will be the cornerstone of the diagnostic process.

## References

1. Selwitz RH, Ismail AI, Pitts NB. (2007) Dental caries. *Lancet*, 369(9555):51-9.
2. Featherstone JD. (2008) Dental caries: A dynamic disease process. *Aust. Dent. J*, 53(3):286-91.
3. Conrads G, About I. (2018) Pathophysiology of Dental Caries. *Monogr Oral Sci*, 27:1-10
4. GBD 2017 Disease and Injury Incidence and Prevalence Collaborators. (2018) Global, regional, and national incidence, prevalence, and years lived with disability for 354 diseases and injuries for 195 countries and territories, 1990-2017: A systematic analysis for the Global Burden of Disease Study 2017. *392(10159)*: 1789–858.
5. Foros P, Oikonomou E, Koletsi D, Rahiotis C. (2021) Detection Methods for Early Caries Diagnosis: A Systematic Review and Meta-Analysis. *Caries Res*. 55(4)247-59.
6. Shafer W. *Textbook of Oral Pathology*. 6<sup>th</sup> ed. New Delhi: Elsevier; 2009. p. 567.
7. Fejerskov O. (1997) Concepts of dental caries and their consequences for understanding the disease. *Community Dent Oral Epidemiol*. 25(1):5-12.
8. Carounanidy U, Sathyanarayanan R. (2009) Dental caries: A complete changeover (Part II)-changeover in the diagnosis and prognosis. *J Conserv Dent*. 12(3):87-100.
9. Gomez J. (2015) Detection and diagnosis of the early caries lesion. *BMC Oral Health*. 15 Suppl 1:S3.
10. Abogazalah N, Ando M. (2017) Alternative methods to visual and radiographic examinations for approximal caries detection. *J Oral Sci*. 59(3):315-22.
11. Ie YL, Verdonschot EH. (1994) Performance of diagnostic systems in occlusal caries detection compared. *Community Dent Oral Epidemiol*. 22(3):187-91.
12. Ismail AI. (1997) Clinical diagnosis of precavitated carious lesions. *Community Dent Oral Epidemiol*. 25(1):13-23.
13. Peers A, Hill FJ, Mitropoulos CM, Holloway PJ. (1993) Validity and reproducibility of clinical examination, fibre-optic transillumination, and bite-wing radiology for the diagnosis of small approximal carious lesions: An in vitro study. *27(4)*:307-11